DRS PAUL AND ALEXANDRE MIARA AND F. CONNOLLY

How to control layering?

CV FLASH

Dr Paul MIARA
• Dental surgeon

Dr Alexandre MIARA
• Dental surgeon

Dr F. CONNOLLY • Dental surgeon

Thanks to continuous improvements in composite materials and bonding techniques, it is now possible to offer our patients dependable, good-looking restorations which last a considerable time, if certain conditions are met. The authors explain.

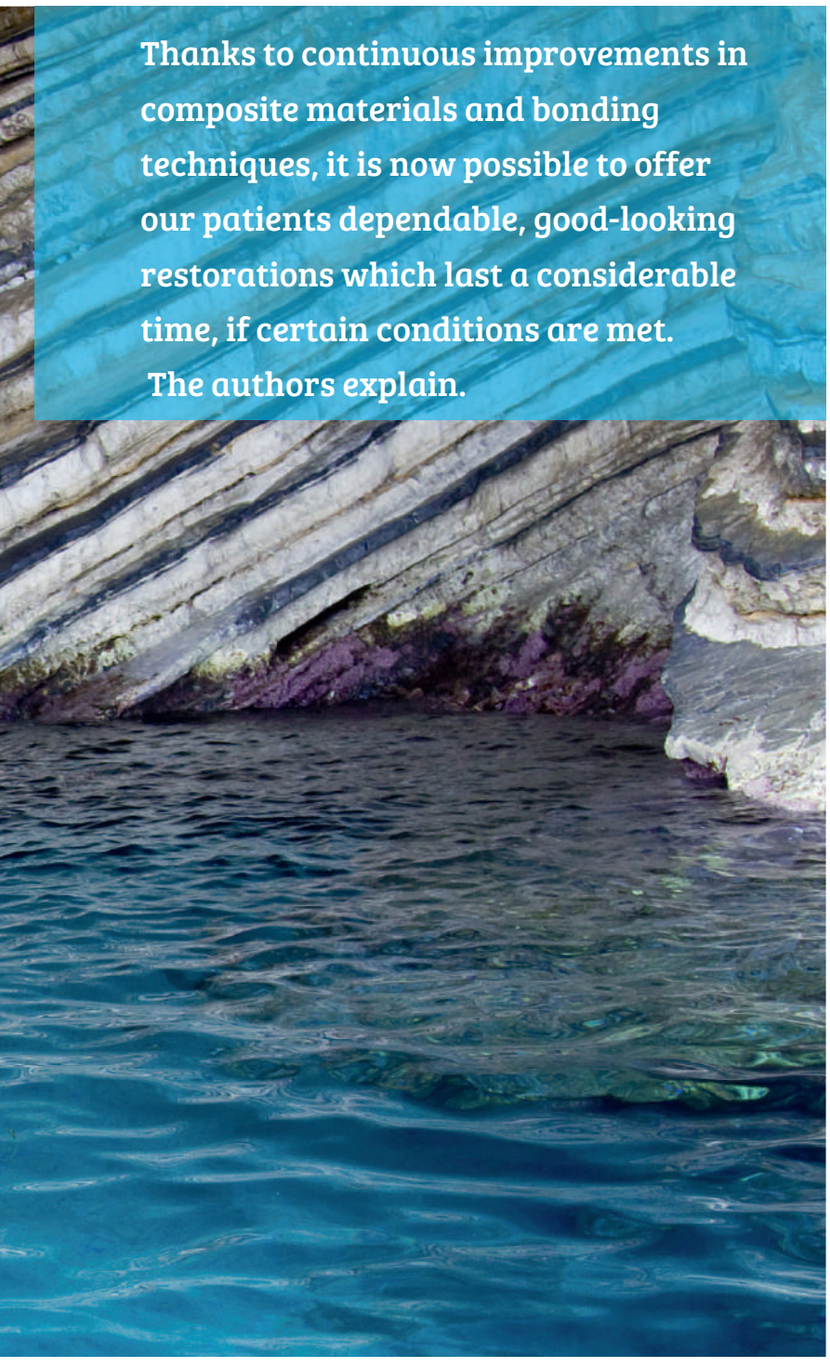

Composite fillings are now the preferred alternative to alloy-based materials. More and more patients are refusing to have any new metallic fillings; some are even asking for their old amalgam ones to be replaced with more aesthetic materials. Composite materials continue to improve steadily, and bonding techniques even more so; this means we can offer our patients dependable, good-looking restorations which last a considerable time – provided certain conditions are met: the right choice of composite, a layering technique which allows guided shrinkage on curing (polymerization), minimum curing stress, proper rebuilding of the contact point and the correct occlusal anatomy.

THE PRINCIPLE OF CONTROLLED LAYERING

Direct composite placement in the posterior part of the mouth demands a rigorous approach and a perfect understanding and command of the methods involved. (Fig. 1).

The layering must:

- *provide a perfect seal at the cervical, proximal and occlusal edges.*
- *enable a contact point or surface to be rebuilt.*
- *reproduce the occlusal anatomy without difficulty.*

Many layering techniques have been proposed for rebuilding the proximal surface: all aim to reduce composite curing constraints and stress.
For horizontal layering successive applications are recommended, none more than 2mm thick.
Oblique layering is fairly hard to do, especially in a deep and narrow proximal area. The technique consists of managing the vectors of polymerization by putting the light source against the cusps, so directing polymerization preferentially in the direction of the dental tissues.

Fig. 1: *Diagram of the controlled layering technique, showing front and side views of the four essential stages. Each stage involves one addition of composite which is light-cured before moving on to the next stage.*

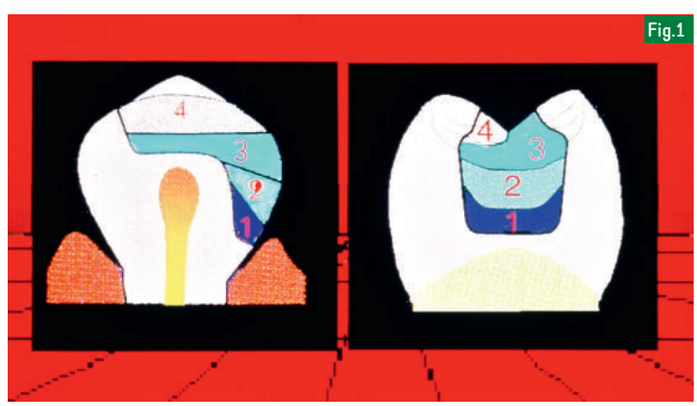

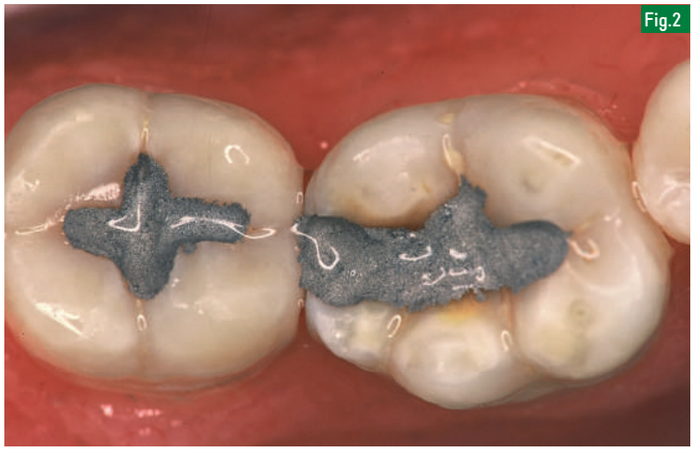

Fig. 2: *This patient presented with two recent amalgam fillings: they had been properly done, but she was adamant she wanted to change them for two better-looking restorations.*

Fig. 3: *Setting up an operating field before removing the amalgam fillings.*

Fig. 4: *The amalgam fillings are removed with a burr drill under water spray.*

Fig. 5: *The shaping of the cavities is done with fine-grained diamond tools.*

Fig. 6: *The cavities must have certain characteristics: a wide isthmus, a minimum thickness of about 2 mm, and no bevel at the edges. The cavities need not be retentive: the filling will be securely held by the adhesive.*

Lutz proposed another technique known as the "three-site technique", still using light transmittance polymerization. This requires a transparent matrix band and an interdental wedge so that the light could be directed to the marginal zone during light curing. That technique was very soon abandoned as too complex in practice; also, transparent matrix bands could not be pre-formed. We should now like to suggest a four-stage controlled layering technique ideally suited to Class II cavities.

The first stage establishes a seal at the cervical and proximal edges. The initial application involves putting a small amount of composite at the cervical edge and condensing it with a smooth condenser so as to get a very thin layer along the vestibular and lingual walls of the proximal cavity. This layer must never come up as high as the contact point.

The second stage is entirely devoted to preparing the contact point.

The third and fourth stages are for construction of the occlusal anatomy; oblique layering will be needed, using small applications of composite.

Clinical case study

We wanted to use a clinical case study to illustrate the various stages required for a class I or class II composite filling in a lower molar. Our patient wanted us to replace two amalgam fillings (Fig. 2), which her dentist had made only eight days earlier, because she did not care

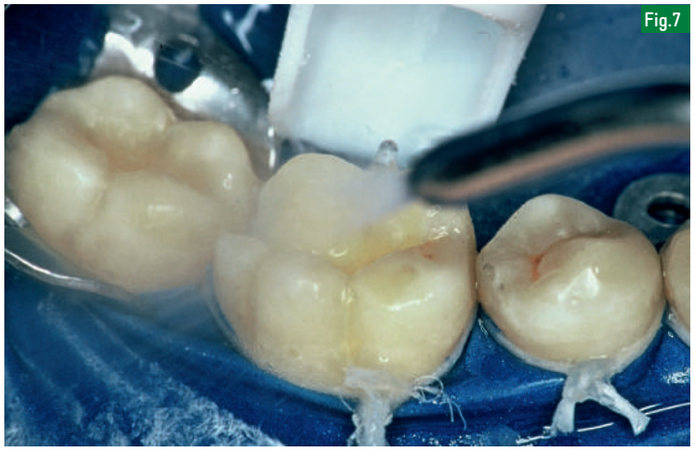

Fig. 7: *The cavities are cleaned using a wet sandblaster to eliminate any trace of amalgam.*

Fig. 8: *Setting up the metal matrix band (Palodent).*

Fig. 9: *A wooden wedge and a McKean separator keep this band in the right place.*

Figures 10 and 11: *The cavities are disinfected using Tubulicid.*

for the look of these metallic fillings.
We decided to replace them with two composite fillings using the direct technique. The first thing to do, particularly when amalgam fillings are to be removed, is to seal off an operating field (Fig. 3), to avoid any swallowing of alloy. The amalgam fillings are removed with a burr drill under water spray using coarse diamond (Green Ring) instruments, (Fig. 4). finishing with fine diamond instruments (Fig. 5), preferably ones with a rounded internal angle; it is not necessary to try for a preparation with no undercut, as in the case of indirect techniques. Nevertheless, it is always preferable to have a wide isthmus and a minimum thickness of about 2mm, so as to ensure the composite reconstruction does not fracture under mastication forces; (Fig. 6). The preparations must have no bevel, even in the cervical zone.
The prophylactic extension principles described by **Black** need not be applied because the bonding provides sufficient chemical retention.

We use a wet sandblaster to make sure the cavities are perfectly clean; (Fig. 7) this removes any drilling waste and, still more important, every trace of amalgam. Then we insert a thin metal matrix band using special tweezers; (Fig. 8).
The *Palodent* matrix band is easy to put against the mesial surface of the next molar; having adjusted the height we check that it comes well beyond the cervical and proximal edges. A wooden wedge and a *McKean* separator make the preparation secure; (Fig. 9).

The cavities are cleaned using a *benzalkonium chloride solution (Tubulicid)*; (Fig. 10) to be sure it is properly disinfected before bonding; (Fig. 11).

Although Itena's *IperBond Ultra* is a self-mordanting one-bottle adhesive, we prefer

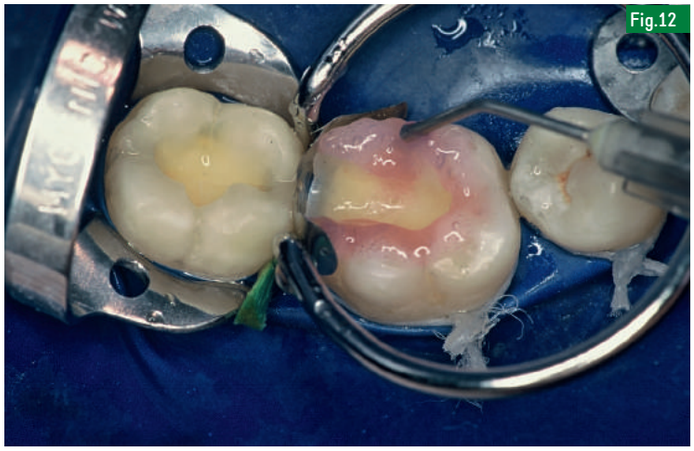

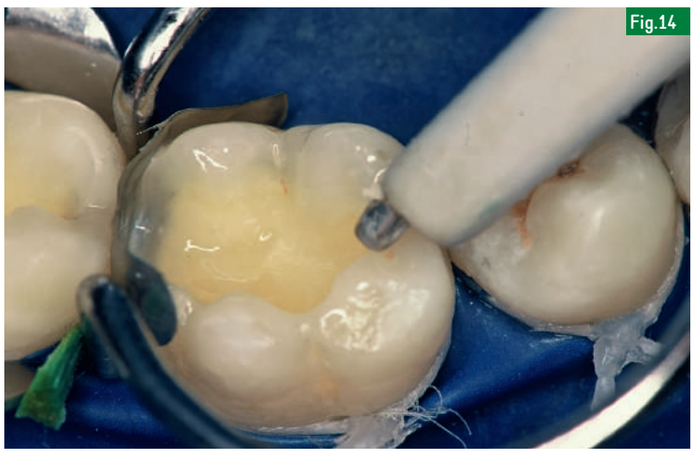

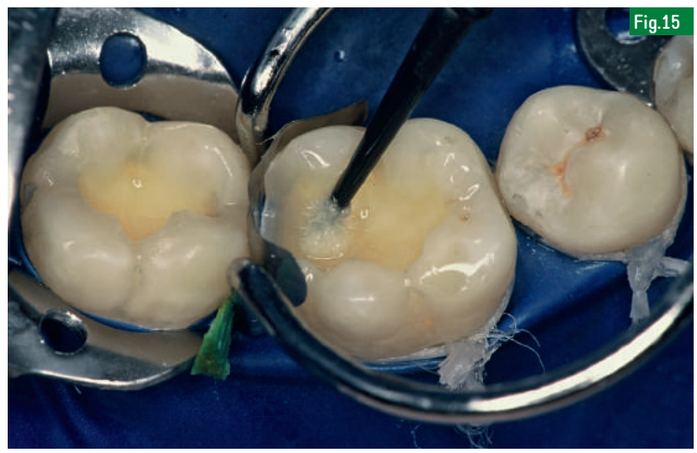

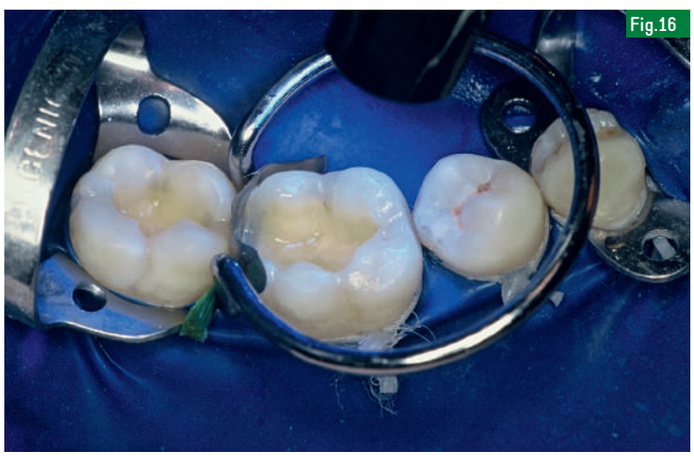

Figures 12 and 13: *The edges are mordanted for 15 seconds, then the entire cavity for 10 seconds.*

Fig. 14: *When the phosphoric acid has been rinsed away, the cavity is dried slightly.*

Fig. 15: *The adhesive (IperBond Ultra by Itena) is applied to the whole of the cavity for 20 seconds, using a microbrush.*

Fig. 16: *Curing of the adhesive for 20 to 30 seconds.*

to mordant the cavity edges slightly (Fig. 12) with 37% orthophosphoric acid, left on for 20 seconds and then spread over the whole surface of the tooth with a microbrush (Fig. 13) for ten seconds or so. The acid is then thoroughly rinsed away and the cavity dried a little, (Fig. 14)but not much: it must not be too dry when the adhesive is applied. IperBond Ultra is applied to the whole of the cavity for 20 seconds, using a microbrush to massage the dentine and enamel for better penetration; (Fig. 15). when the adhesive has been left to dry for a few seconds while its solvents evaporate, it is cured for 20 to 30 seconds. (Fig. 16).

This first application is crucial: by creating a hybrid sealing layer it provides the best possible protection against physical, chemical and bacterial attack; moreover it reduces postoperative sensitivity, and ensures a proper bond between tooth and composite.

Reconstructing the cusp anatomy

Once this biological barrier is in place the layering begins with the application of a small amount of Itena *Reflectys* composite at cervical level. The composite is pressed down with a smooth condenser (Fig. 17) to ensure a good cervical and proximal seal; (Fig. 18). The second application of composite is roughly at the level of the proximal cavity, and needs to be sufficient to create a contact point (Fig. 19).

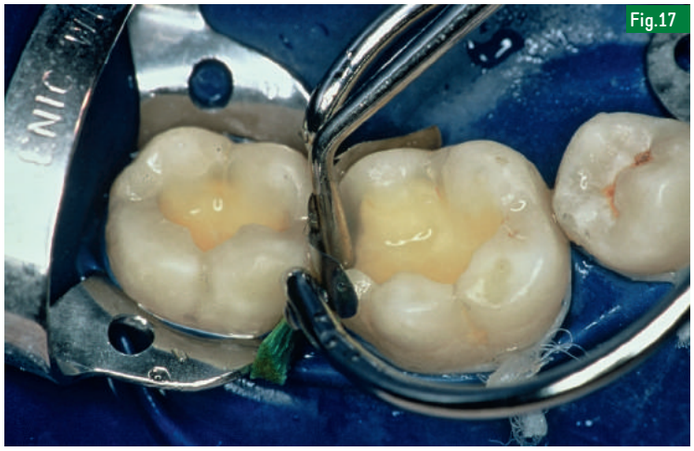

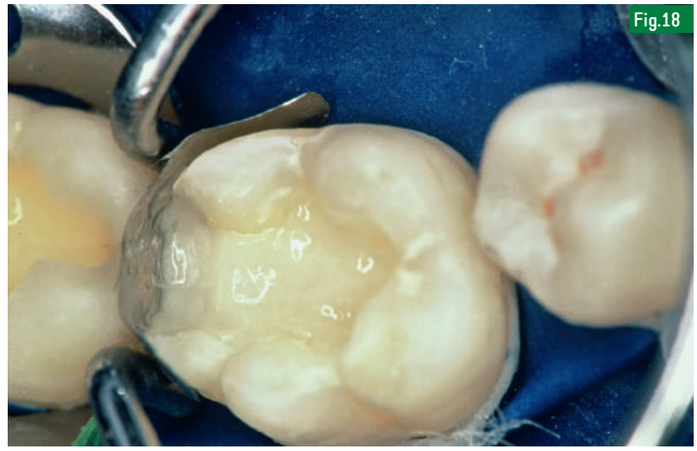

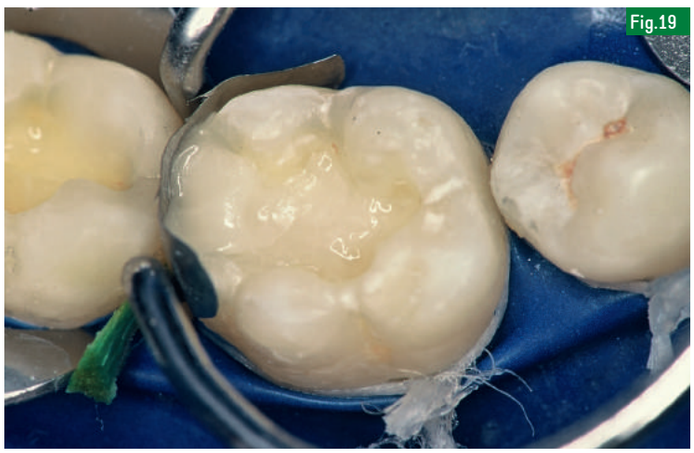

Fig. 17: *The first stage in controlled layering aims to ensure a good seal at the cervical and proximal edges. A thin layer of composite will be laid down at the edges using a smooth condenser.*

Fig. 18: *This first application of composite ensures a good cervical and proximal seal.*

Fig. 19: *Second application of composite, at the level of the secondary cavity. This creates the contact point.*

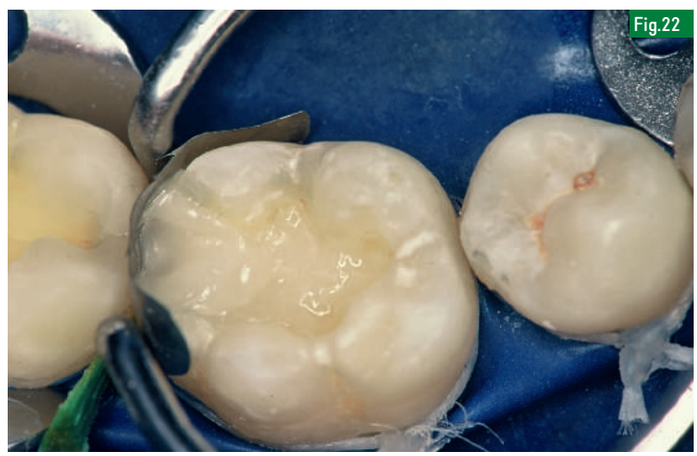

Fig. 20: *Smooth-nib condenser.*

Fig. 21: *The condenser presses the matrix band hard against the next tooth at the level where the contact point will be.*

Fig. 22: *After curing, a second application finally fixes the position of the contact point.*

Using a smooth broad-nib condenser (Fig. 20) we get into the mass of the composite and press the condenser nib hard at the level of the contact point, taking care that the nib does not entirely disappear into the composite; (Fig. 21).
A quick curing stabilizes the composite, and above all keeps the matrix band perfectly attached to the posterior molar. (Fig. 22).
Once we are sure the edges are well sealed and the contact point has been made, we can move on to the final stage of controlled layering and rebuild the cusp anatomy. One initial application locates each cusp; (Fig. 23), then, using ceramic stain (Fig. 24) mixed with a liquid resin *(Fortify Bisico)*, we tint the bottoms of the grooves slightly for ease of location during the final layering; (Fig. 25). The last applications are done in the form of small pellets placed side by side; a more natural

The last applications are done in the form of small pellets placed side by side.

Fig. 23: *A third application of composite is needed to locate where the cusps will be.*

Fig. 24 and 25: *An orange-tinted ceramic stain mixed with a liquid resin makes it easy to colour the bottoms of the grooves.*

Fig. 26: *The small pellets of composite are moved around with a probe to create a natural occlusal anatomy.*

Fig. 27: *Gaps are closed using a transparent composite.*

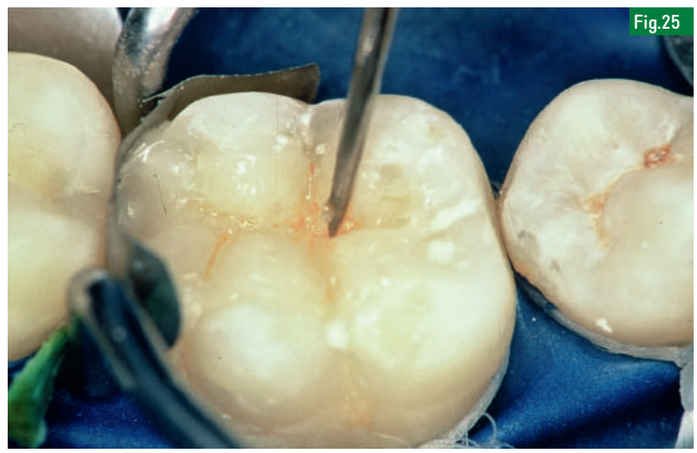

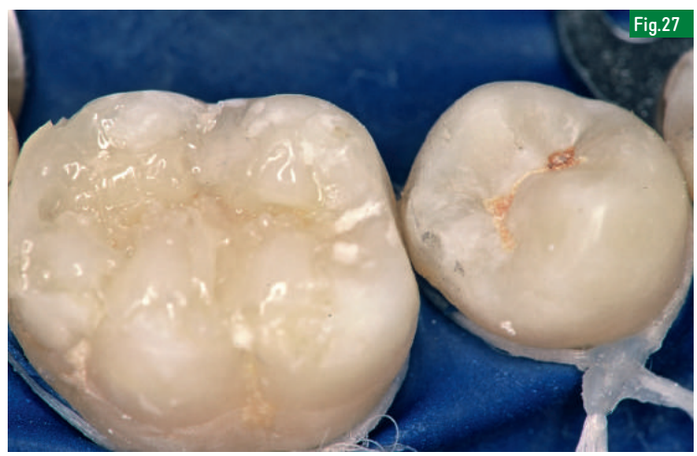

cusp anatomy is created (Fig. 26), by moving these pellets around. After a short curing the space is closed by applying a layer of more transparent composite; (Fig. 27). and the layering ends with a long polymerization (30 to 45 seconds).

Layering technique

Composite placement will be more straightforward in the case of the second molar, which is a simple cavity. After creating the hybrid layer (Fig. 28), an initial application followed by staining of the groove bottoms allows the cusp positions to be found again; (Fig. 29). The pellet technique is then used to recreate a natural occlusal anatomy. (Figures 30 and 31).

Once the layering is finished the occlusal anatomy is perfected with tungsten or fine-grained diamond tools. (Figures 32 and 33). Before adjusting the occlusion we mordant lightly with 37% orthophosphoric acid for approximately 30 seconds, then rinse and dry all fillings, and apply a liquid resin *(Fortify)* to ensure a perfect seal at the margins and close any surface porosities. (Fig. 34). Once adjustment of occlusion is completely finished (Fig. 35), we polish the composites using a diamond paste. (Fig. 36).

Then comes a very important stage which will make sure of the seal at the edges. To do that we re-mordant all of the composite surfaces, going well beyond the edges (Fig. 37); we leave the phosphoric acid on for five to ten seconds, then rinse off, dry, and apply one or two coats of liquid resin. Before this surface layer of resin is cured it must be spread with the air puffer.

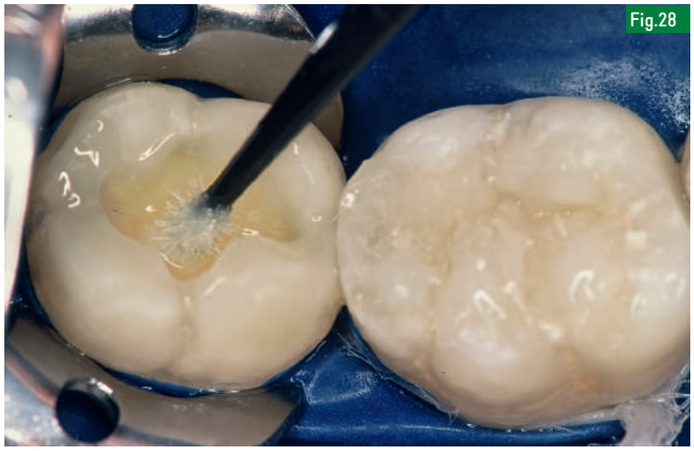

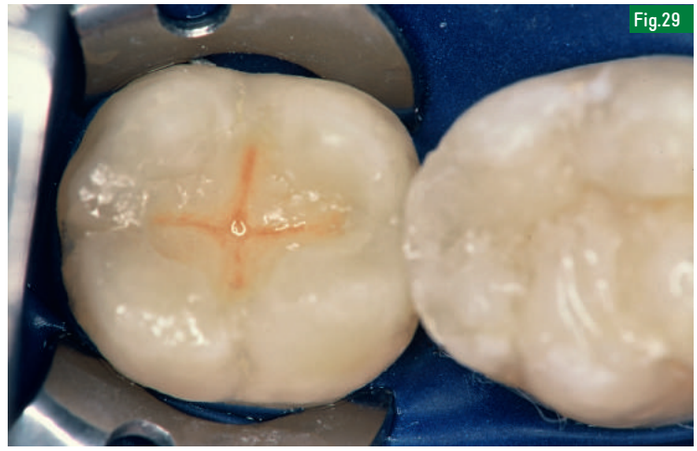

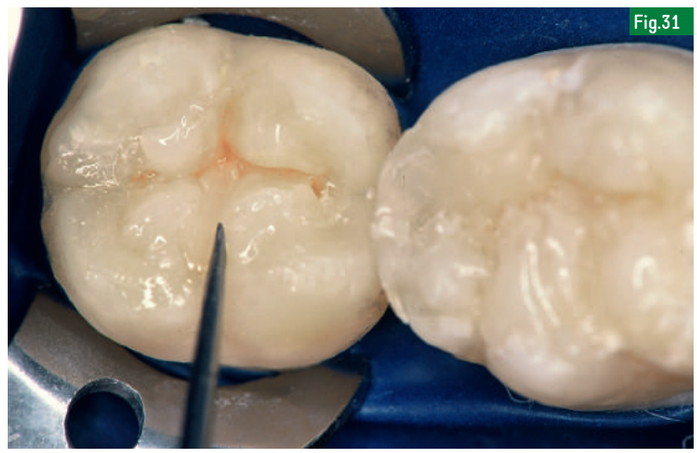

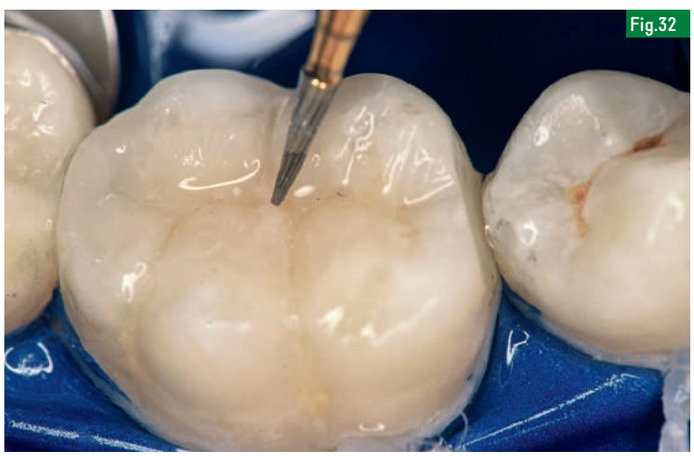

Thanks to a good layering technique, and above all to the aesthetic quality of the *Reflectys* composite, these fillings reproduce the look of the natural tooth perfectly (Fig. 38).

Fig. 28: *After mordanting, adhesive is applied to the second molar.*

Fig. 29: *Once the groove bottoms have been stained with a ceramic stain, the cusps are built up by adding a little at a time.*

Fig. 30: *Small increments in pellet form enable us to build up the occlusal surface by addition.*
Fig. 31: *An application of transparent composite closes any gaps.*

Figures 32 and 33: *The composites are shaped with tungsten or fine-grained diamond tools, always under water spray.*

Optical qualities

Controlled layering remains a simple technique, which uses successive applications of composite to give perfect sealing of the cervical and proximal areas, to build a reliable contact point or surface and make it easier to model the occlusal anatomy. To some extent it also mitigates the constraints arising from stress and shrinkage while the composite is being cured. The optical qualities of latest-generation nano-hybrid materials such as *Reflectys*, which we have used here to restore the two molars in association with IperBond Ultra adhesive, enable us to reproduce the look of natural teeth.

Choice of composite and adhesive:

Itena Reflectys is a light-cured anterior/posterior nano-hybrid composite available in 16 tints; the range of opacities makes it possible to choose the ideal colour for fillings in front or back teeth. Apart from its optical qualities, the composite is highly thixotropic, which is essential for assembly by layering. Furthermore it does not stick to instruments, making it easier to build up the filling bit by bit. *Itena's IperBond Ultra* is a single-bottle adhesive, and may be used with or without prior mordanting. Bonding to enamel and to dentine are both excellent.

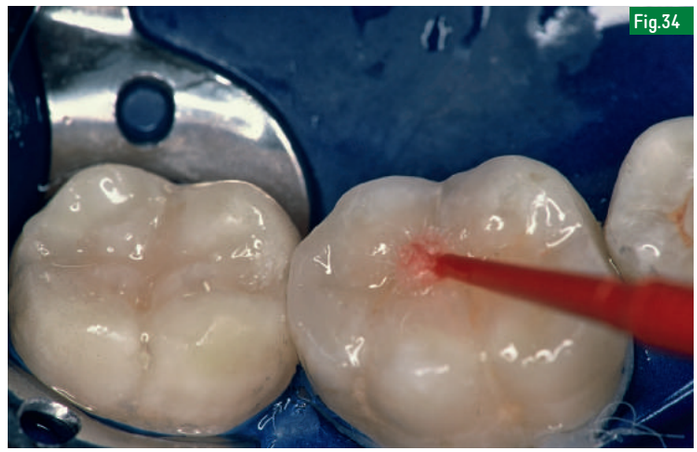
Fig.34

Fig. 34: *After a short mordanting, a light-cured liquid resin spread over the whole of the filling seals the edges and closes the composite's surface porosities.*

Fig.35: *How the fillings look after the adjustments to occlusion have been finished.*

Fig. 36: *Polishing the fillings with a diamond paste.*

Fig. 37: *Mordanting the whole of the fillings.*

Fig. 38: *A light-cured liquid resin ensures a good final seal on these aesthetic restorations. Note the optical qualities of the composite (Reflectys; Itena).*


Fig.35


Fig.36


Fig.37


Fig.38